

**On behalf of Vision Expo, we sincerely thank you for being with us this year.**

**Vision Expo Has Gone Green!**

We have eliminated all paper session evaluation forms. Please be sure to complete your electronic session evaluations online when you login to request your CE Letter for each course you attended! Your feedback is important to us as our Education Planning Committee considers content and speakers for future meetings to provide you with the best education possible.



1

---

---

---

---

---

---

---

**DISCLOSURES**

Melody Tavakoli has received honorarium from Johnson & Johnson, Topcon, Visionix and Essilor.

She is an ongoing Professional Affairs Consultant for JnJ.

She has done some consulting for Topcon, Essilor and Visionix through SightLine Ophthalmic Consulting.

All relevant relationships have been mitigated.

2

---

---

---

---

---


---

---

**Clearing the View:  
Contact Lens  
Challenges**

**MELODY TAVAKOLI OD**

COO - SightLine Ophthalmic Consulting  
Owner - See Me Optometry La Jolla, CA



3

---

---

---

---

---

---

---



- Private Practice in San Diego, CA
  - Experience in Multiple Practice Modalities
- Sightline Ophthalmic Consulting COO
- Professional Affairs Consultant for Johnson & Johnson Vision

DRTAVCONSULTING@GMAIL.COM  
WWW.SEEMEOPTOMETRY.COM  
@SEEMEOPTO

4

---

---

---

---

---

---

---

## STATISTICS OVERVIEW

### Prevalence

- As of 2023, an estimated **45-46 million individuals** in the U.S. wear contact lenses, with **females accounting for approximately 67-70%** of wearers.<sup>1</sup>

### Non-Compliance

- **Over 72%** of users demonstrate some level of non-compliance, with particularly low rates for behaviors like lens case cleaning (**only 24% compliant**).<sup>2</sup>

### Contact Lens Complications

- **18.8%** of wearers developed microbial keratitis (MK) and **20.4%** experienced non-microbial keratitis, often due to hygiene lapses and overnight wear.<sup>3</sup>

### Prevalence of Complications

- Between **30% and 40%** of contact lens users report experiencing at least one complication (e.g., dryness, redness, infection), consistent across multiple global studies.<sup>4</sup>

1. Randag et al., 2020; Sakr et al., 2024. 2. Gammon & Arbour, 2022. 3. Sakr et al., 2024. 4. Dumbleton et al., 2015; Randag et al., 2020

5

---

---

---

---

---

---

---



## TYPES OF CLs

### •HARD VS SOFT

- SINGLE USE/DAILY DISPOSABLE
  - Sphere, Toric, Multifocal, Multifocal Toric

### •REUSABLE

- 2 week or 1 month

### •EXTENDED WEAR

- 6 nights continuous wear
  - Precision 7, AV Oasys '2-week'
- Up to 30 nights continuous wear
  - Air Optix Night+Day

6

---

---

---

---

---

---

---

## CONTACTS VS GLASSES



### CONTACTS

- Convenience
- Aesthetics
- Sports/Physical Activities
- Peripheral Vision
- Wrapped Sunglasses



### GLASSES

- Prescriptions/prism
- Protection
- Little/no complications

7

---

---

---

---

---

---

---

## FUN FACTS



About **50%** of wearers say they **sleep or nap** in their lenses, at least occasionally.



Nearly **half** admit **extending lens replacement** beyond recommended schedules (e.g., wearing 2-week lenses for 3+ weeks).



Over **80%** keep their lens case longer than recommended, and **55%** "top off" solution instead of discarding old solution.



**84.9%** shower with lenses in, and **61%** swim in them, exposing lenses to tap or pool water, which can harbor microbes.

8

---

---

---

---


---

---

---

## REAL PATIENT CONFESSIONS

- "I put the contacts on one side of the case to save solution"
- "I never change the solution, just top off"
- "I wait until they hurt, then change them out"
- "I didn't know daily CLs mean you only wear them one day"
- "I've been wearing the same pair of contacts all year"

WHAT HAVE YOU HEARD?!? 

9

---

---

---

---

---

---

---

**TYPES OF COMPLICATIONS**

INFECTIOUS

INFLAMMATORY

MECHANICAL

ALLERGIC

IF YOU ABUSE CLs,  
THEY WILL ABUSE YOU BACK!

10

---

---

---

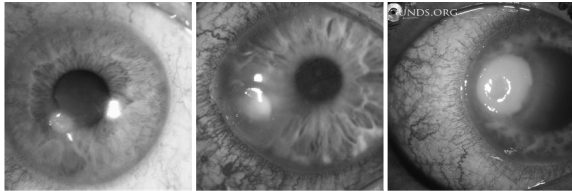
---

---

---

---

---



**INFECTIOUS COMPLICATIONS**

**MICROBIAL KERATITIS**

11

---

---

---

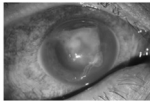
---

---

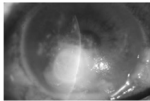
---

---

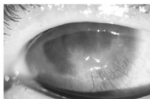
---



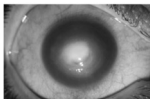
Bacterial keratitis



Fungal keratitis



Viral keratitis



Acanthamoeba keratitis

**MICROBIAL KERATITIS**

- BACTERIAL
  - PSEUDOMONAS
  - STAPHYLOCOCCUS
- ACANTHAMOEBA
- FUNGAL
- VIRAL

12

---

---

---

---

---

---

---

---

FEATURE	BACTERIAL MK	ACANTHAMOEBA	FUNGAL	VIRAL (HSV)
Laterality	Usually unilateral	Usually unilateral	Usually unilateral	Usually unilateral
Onset	Rapid	Insidious	Gradual	Variable (episodic)
Pain	Severe	Out of proportion	Moderate	Mild to moderate
Classic Sign	Purulent ulcer	Ring infiltrate	Feathery margin	Dendritic ulcer
Discharge	Mucopurulent	Minimal	Watery	Watery/serous
Staining	Positive	Infiltrate may stain	Infiltrate stains	Dendrite stains with fluorescein + rose bengal
Treatment	Antibiotics	Biguanides	Antifungals	Oral/topical antivirals

13

---

---

---


---

---

---

---

---



### INFLAMMATORY COMPLICATIONS

CLARE, DRY EYE, HYPOXIA

14

---

---

---

---

---

---

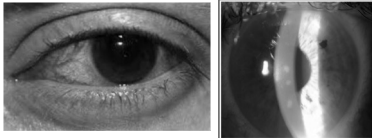
---

---

### CLARE CONTACT LENS ASSOCIATED RED EYE

- Usually unilateral
- Redness of limbus
- Sterile infiltrative keratitis

**INFLAMMATORY**



### SYMPTOMS

- Redness
- Irritation
- Mild pain
- Photophobia
- Watering

15

---

---

---

---

---

---

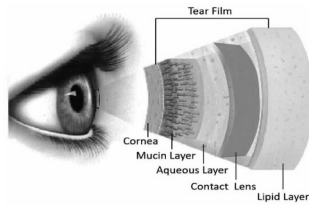
---

---

## **DRY EYE**

- Usually bilateral
- Blurred/fluctuating vision
- Symptoms better when CLs are out

**INFLAMMATORY**



### **SYMPTOMS**

- Dryness
- Redness
- Irritation
- Sandy/gritty sensation

16

---

---

---

---

---

---

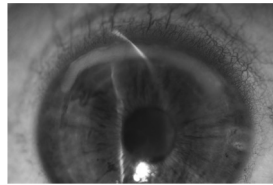
---

---

## **HYPOXIA**

- Edema
- Microcysts
- Polymegethism
- Stromal thinning
- Cornea neovascularization

**INFLAMMATORY**



### **SYMPTOMS**

- All generally asymptomatic

17

---

---

---


---

---

---

---

---



## **MECHANICAL COMPLICATIONS**

CORNEAL ABRASIONS, GPC, SLK

18

---

---

---

---

---

---

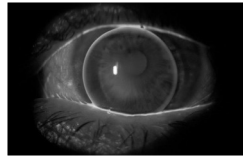
---

---

**CORNEAL  
ABRASION**

- Scrape or epithelial defect
- Usually unilateral
- CL misuse-poor removal technique, lens debris

**MECHANICAL**



**SYMPTOMS**

- Pain
- Tearing
- Photophobia
- Foreign body sensation
- Blurry vision
- Difficulty keeping eye open

19

---

---

---

---

---

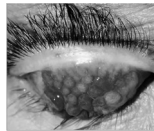
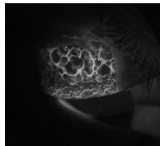
---

---

**GPC  
GIANT PAPILLARY  
CONJUNCTIVITIS**

- Caused by prolonged mechanical irritation
- CL wear w poor hygiene or infrequent replacement
- Usually bilateral

**MECHANICAL**



**SYMPTOMS**

- Extra mucus discharge
- Foreign body sensation
- Fluctuating vision
- Itching
- Lens intolerance

20

---

---

---

---

---

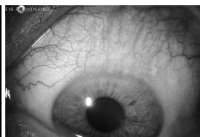
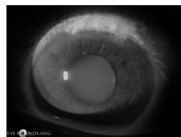
---

---

**SLK  
SUPERIOR  
LIMBIC  
KERATITIS**

- Caused by frictional microtrauma
- Tight upper lids
- Excessive blinking
- Poor tear film
- Tight fitting CLs
- Usually asymmetric bilateral

**MECHANICAL**



**SYMPTOMS**

- Irritation
- Dryness
- Photophobia
- Burning
- Foreign body sensation

21

---

---

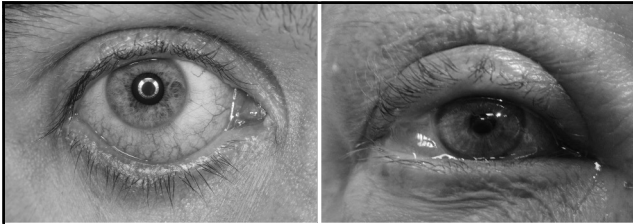
---

---

---

---

---



## ALLERGIC COMPLICATIONS

### CONJUNCTIVITIS, HYPERSENSITIVITY

22

---

---

---

---

---

---

---

### ALLERGIC CONJUNCTIVITIS

- Usually bilateral
- Not caused by CLs, worsened by CLs
- CLs trap allergens

**ALLERGIC**

#### SYMPTOMS

- Redness
- Itching
- Tearing
- Chemosis
- Lid swelling
- Mucus discharge (white ropy/stringy)
- CL intolerance

23

---

---

---

---

---

---

---

### CONTACT LENS HYPERSENSITIVITY

- AKA Solution-Induced
- Usually bilateral
- Delayed Type IV immune response
- Allergy to preservatives

**ALLERGIC**

#### SYMPTOMS

- Redness
- Itching
- CL intolerance
- Burning/Stinging upon CL insertion\*\*

24

---

---

---

---

---

---

---



**THANK YOU!**



**MELODY TAVAKOLI OD**  
COO - SightLine Ophthalmic Consulting  
Owner - See Me Optometry La Jolla, CA

DRTAVCONSULTING@GMAIL.COM  
WWW.SEEMEOPTOMETRY.COM  
@SEEMEOPTO

---

---

---


---

---

---

---

25



---

---

---


---

---

---

---

26



---

---

---

---

---

---

---

27