

On behalf of Vision Expo, we sincerely thank you for being with us this year.

## Vision Expo Has Gone Green!

We have eliminated all paper session evaluation forms. Please be sure to complete your electronic session evaluations online when you login to request your CE Letter for each course you attended! Your feedback is important to us as our Education Planning Committee considers content and speakers for future meetings to provide you with the best education possible.



1

## OCT and OCT Angiography Real World Case Studies for Enhanced Interpretation

Greg Caldwell OD, FAAO  
Carolyn Majcher, OD, FAAO  
Optometric Education Consultants  
Vision Expo West  
Thursday, September 18, 2025



2

### Contact:

- majcher@nsuok.edu
- 918-444-4155

### Disclosures:

- Paid consultant/speaker for:
  - Carl Zeiss Meditec
  - Astellas (Iveric bio)
  - Apellis
  - Regeneron Pharmaceuticals
  - Optomed
- Paid advisory board member for Apellis Pharmaceuticals, LENZ Therapeutics, Notal Vision, Topcon, Tarsus, Genentech

All financial relationships have been mitigated



3

## OCT Hands on Workshop

- Anterior Segment
- Posterior Segment
- Many OCTs to Explore
- Scan and Interpretation

Thursday 12:30pm – 2:30am - Room 2 in Exhibit Hall



Carolyn Majcher, Residency  
Director, Professor, Oklahoma  
College of Optometry...



Shalu Pal, Owner, Dr. Shalu Pal &  
Associates - Yorkville Eye Institute



4

## Disclosures- Greg Caldwell, OD, FAAO

All relevant relationships have been mitigated

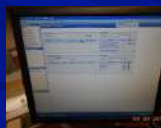- \*\* Lectured for: Alcon, B&L, Dompé, Lenz
- \*\* Disclosure: Receive speaker honorariums
- \*\* Advisory Board: Dompé, Tarsus
- \*\* Disclosure: Receive participant honorariums
- \*\* I have no direct financial or proprietary interest in any companies, products or services mentioned in this presentation
- \*\* Disclosure: Non-salaried financial affiliation with Pharnanex
- \*\* Healthcare Registries – Chairman of Advisory Council for Diabetes and AMD
- \*\* The content of this activity was prepared independently by me - Dr. Caldwell
- \*\* The content and format of this course is presented without commercial bias and does not claim superiority of any commercial product or service
- \*\* Optometric Education Consultants – Scottsdale, AZ, Pittsburgh, PA, Sarasota, FL, Barcelona, Spain, Orlando, FL, Mackinac Island, MI, Quebec City, Canada, and Nashville, TN- Owner



5

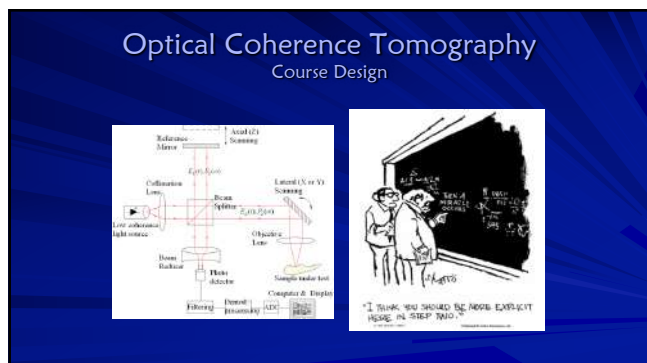
## My Practice

- I am a clinician first then a scientist
- Some are scientists first then clinician
- I need to simplify for patient and patient care.
- Science is great, but not good if there isn't a clinical application.
- Some lectures are science based without clinical application.
- My lecture will be a hybrid. Showing clinical applications of the science

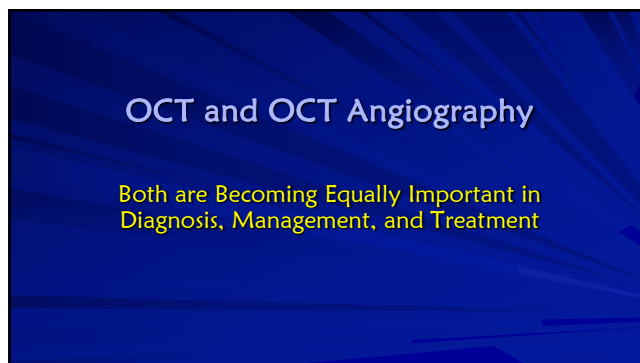


It is wonderful to have someone who's juggling so many aspects of optometry [scientific, clinical experience, teacher & lecturer]. It is

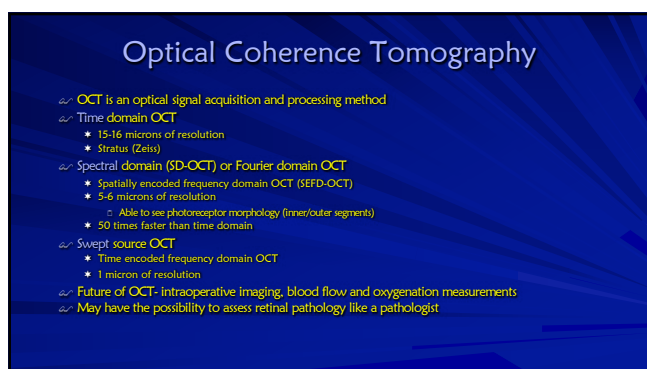
6



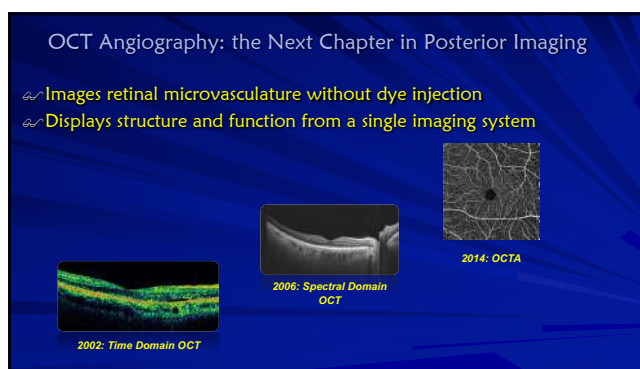
7



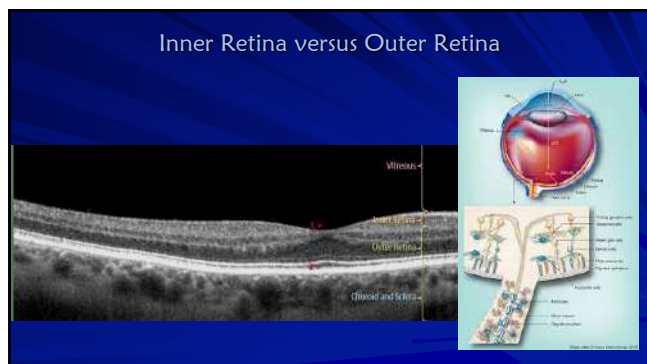
8



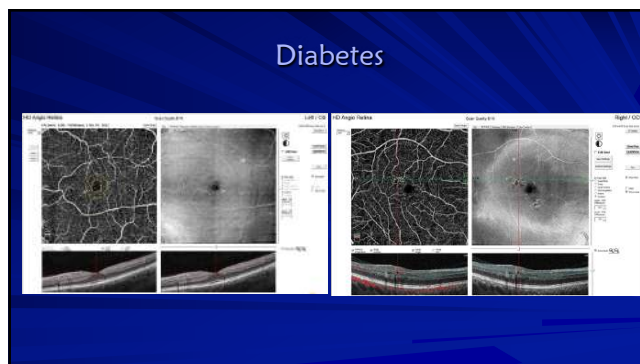
9



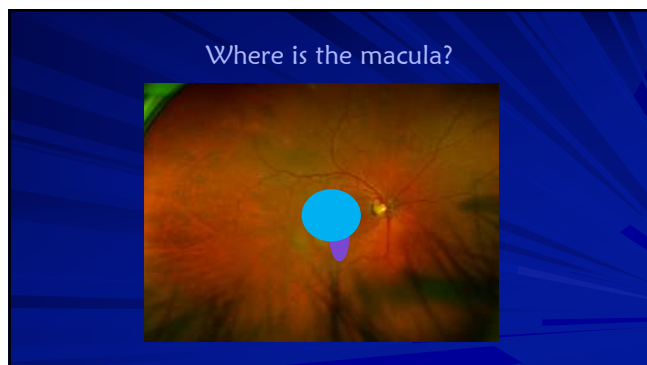
10



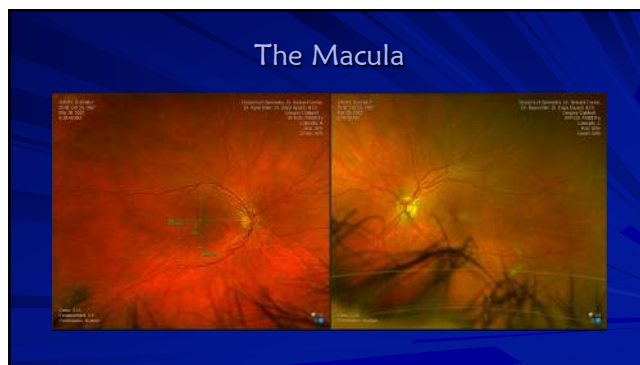
11



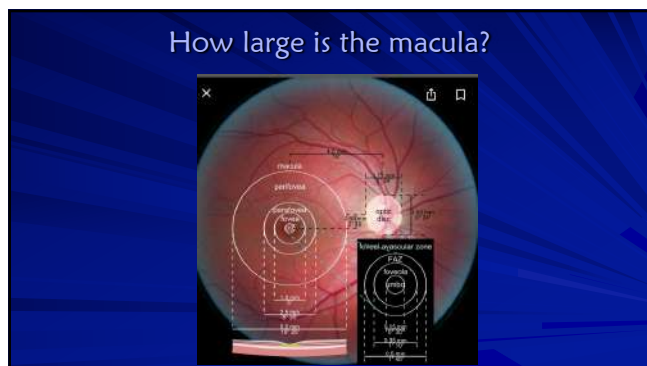
12



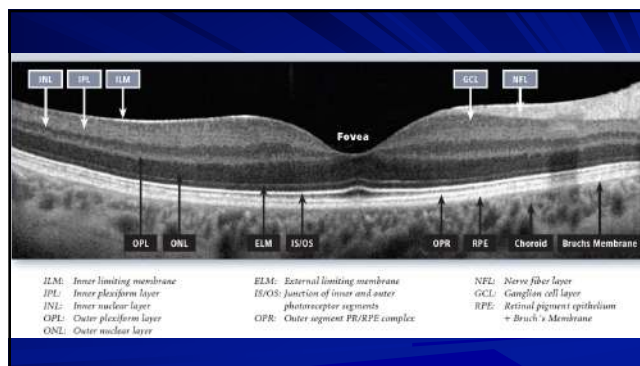
13



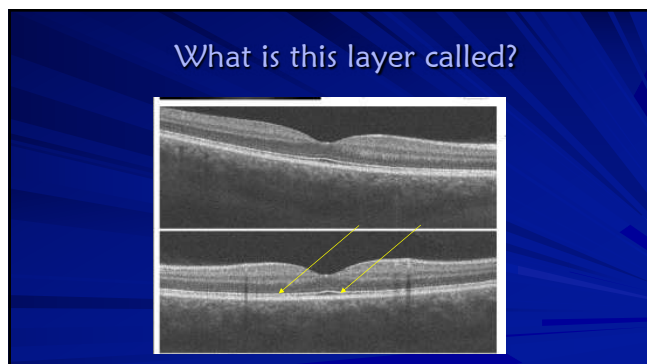
14



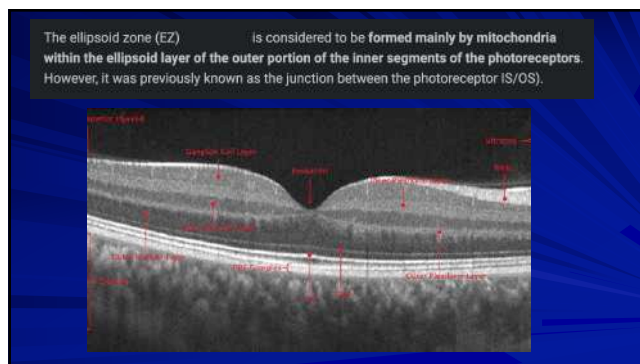
15



16

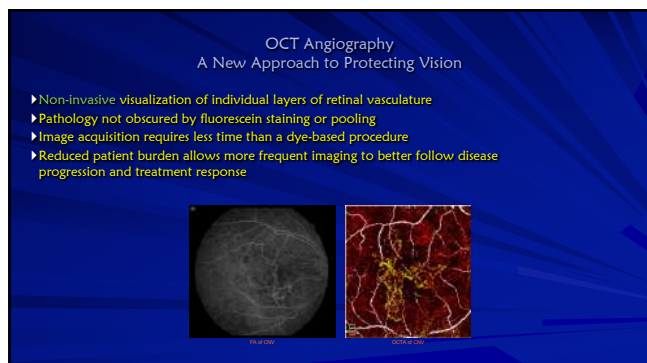


17

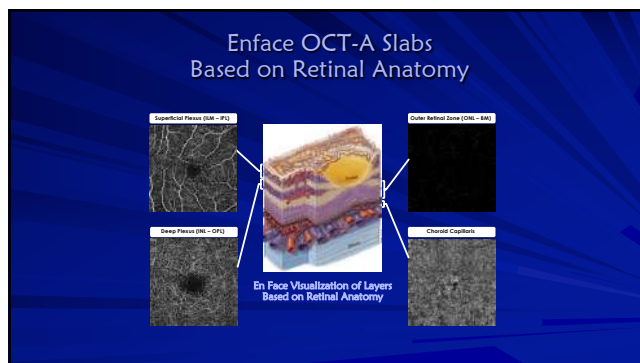


18

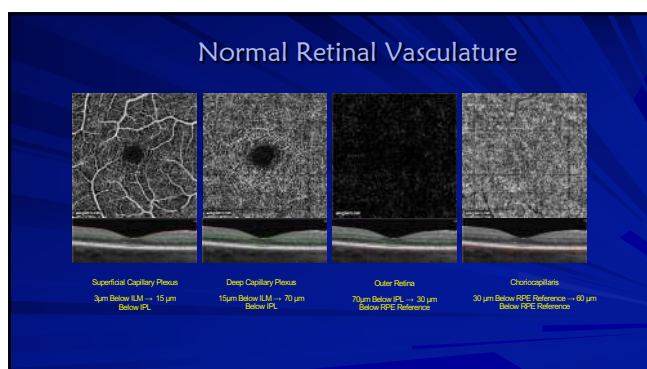




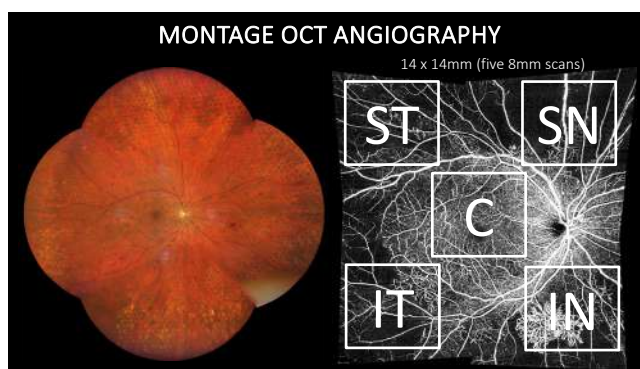
19



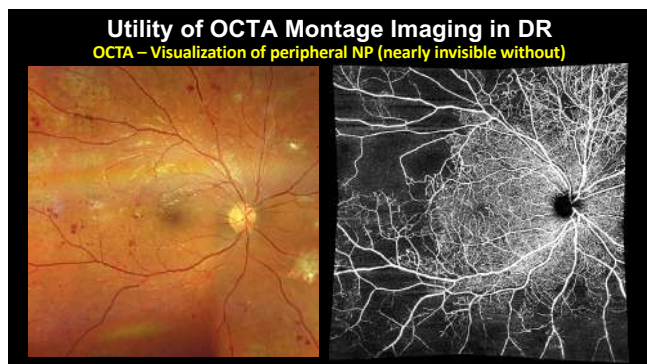
20



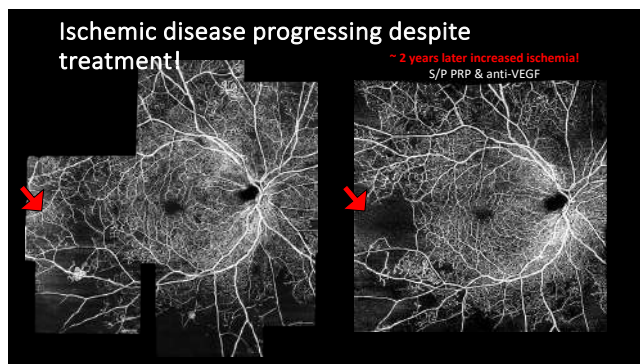
21



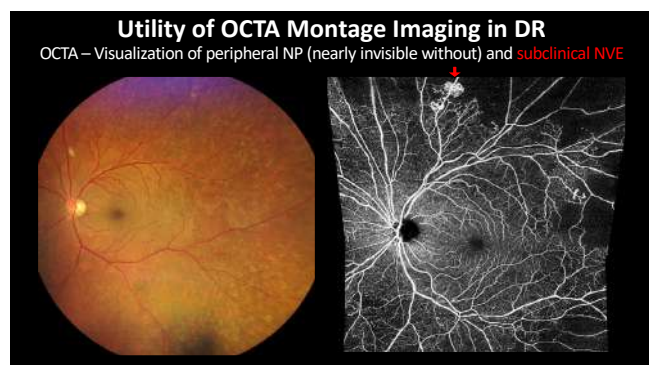
22



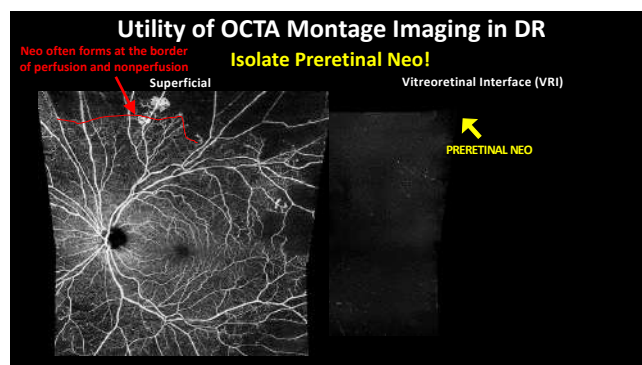
23



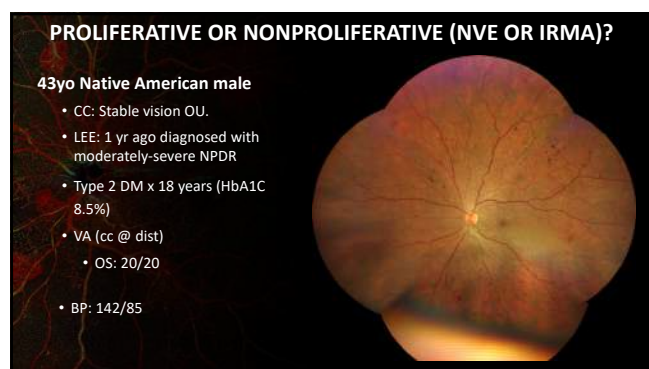
24



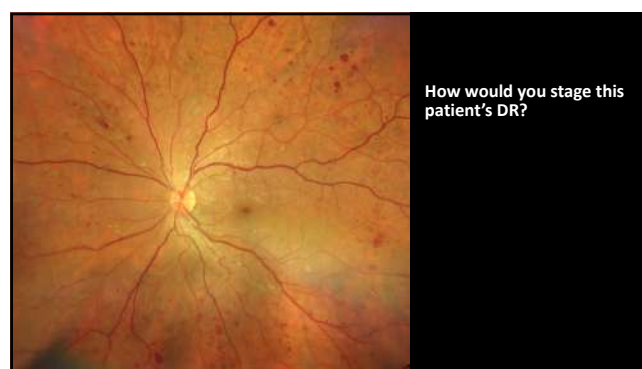
25



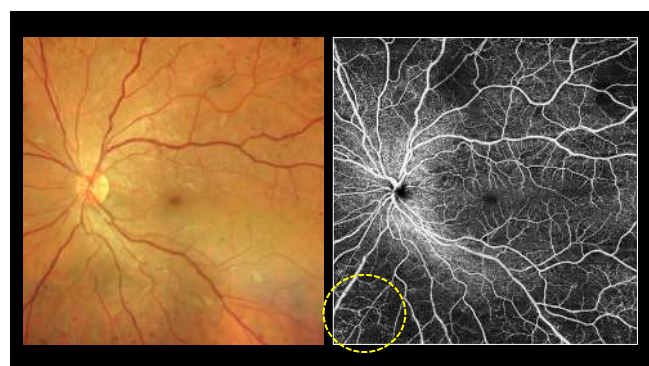
26



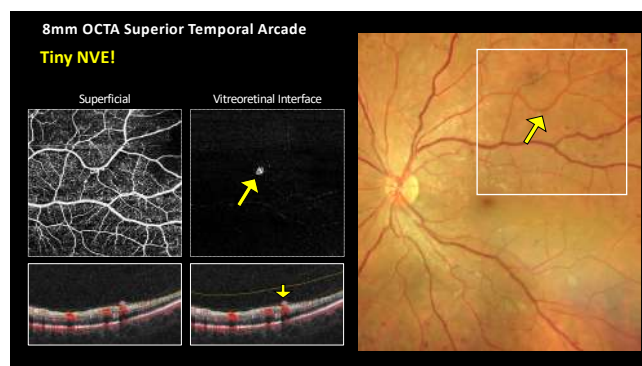
27



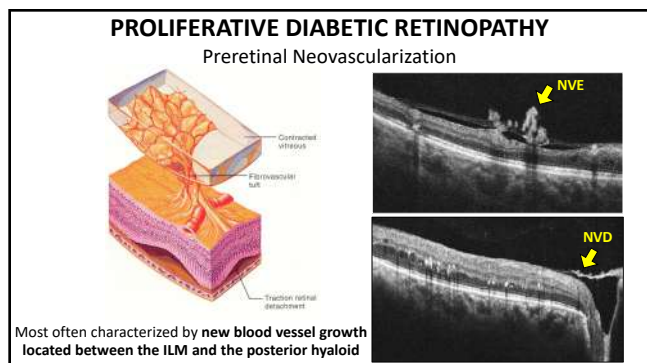
28



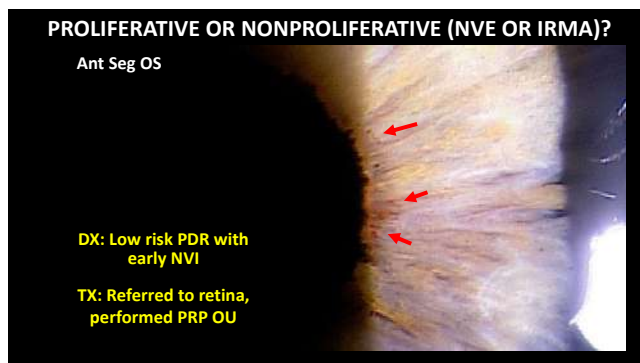
29



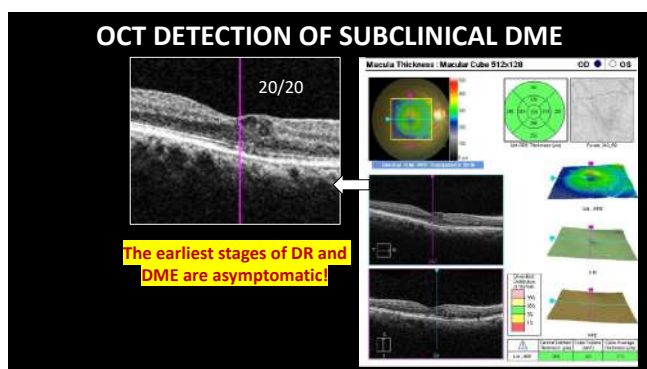
30



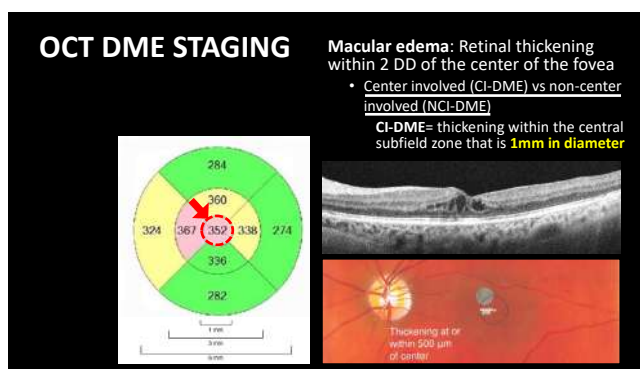
31



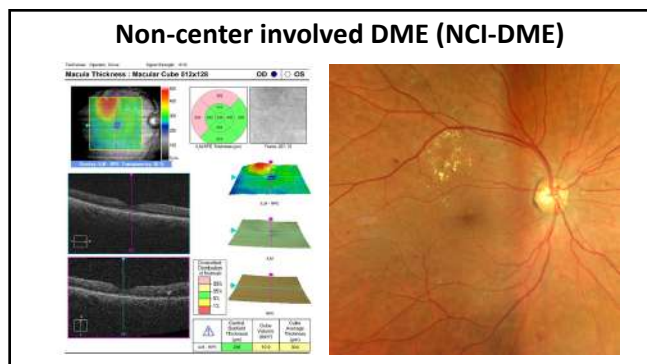
32



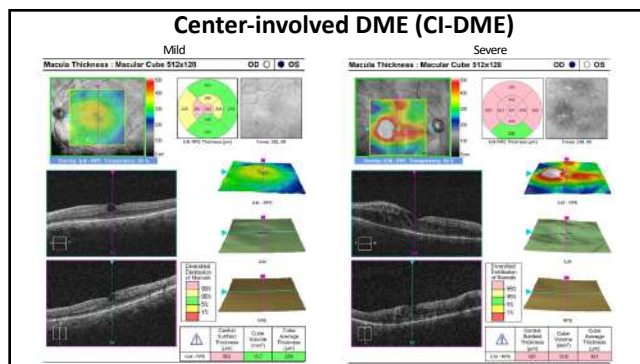
33



34

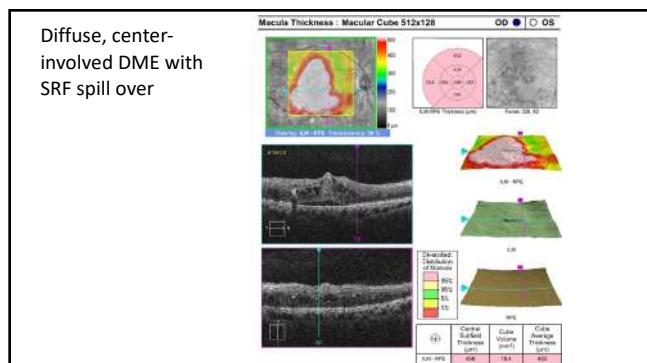


35

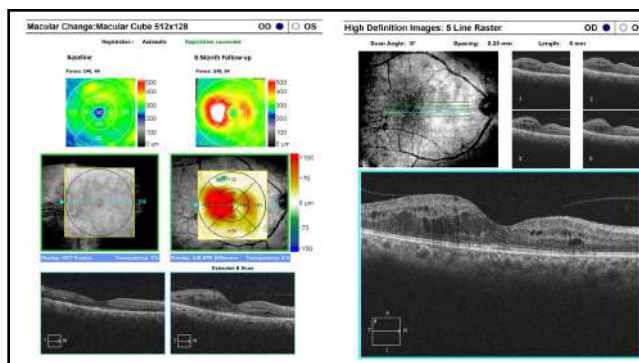


36

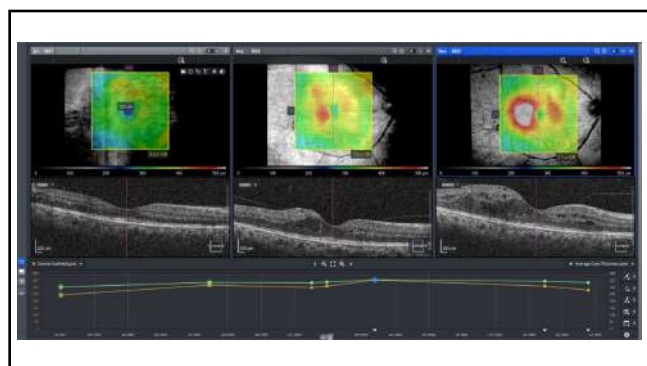




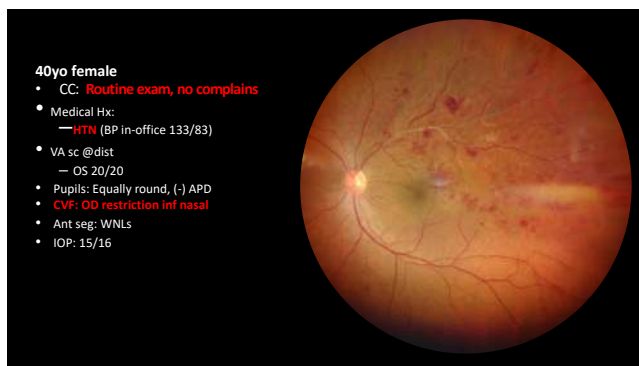
37



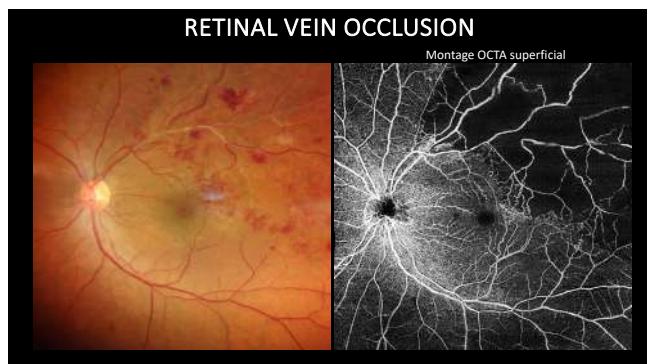
38



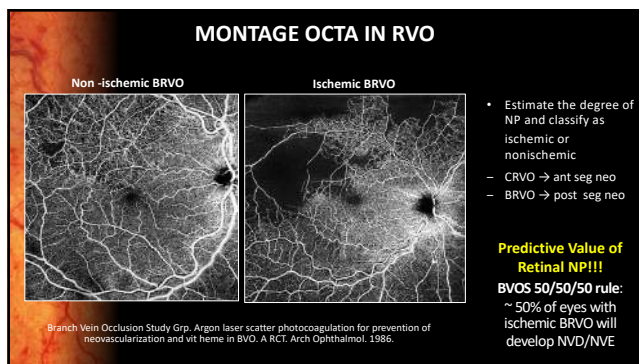
39



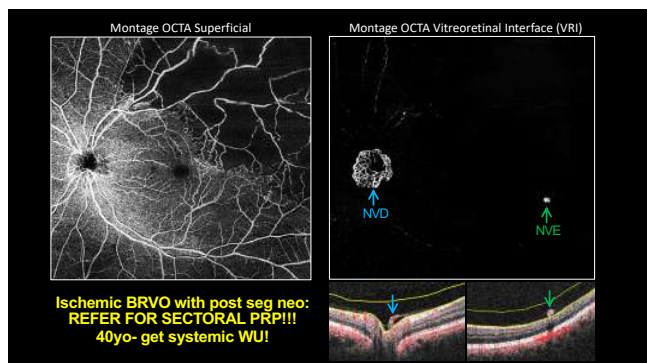
40



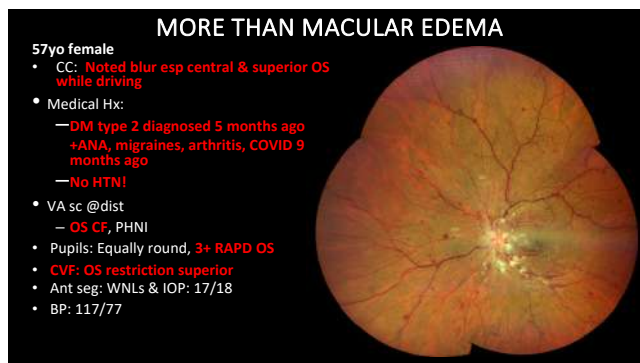
41



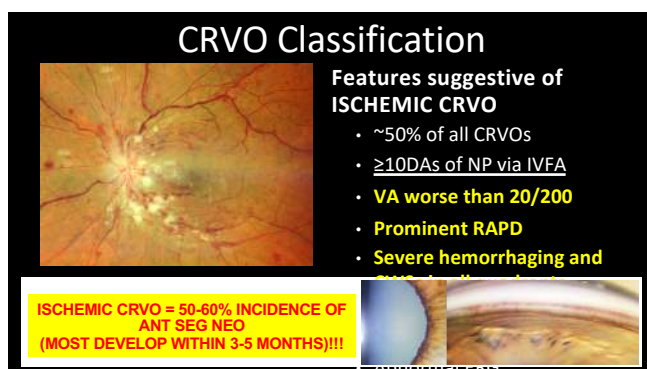
42



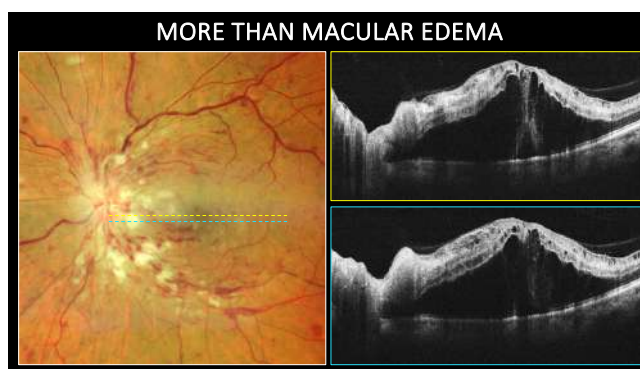
43



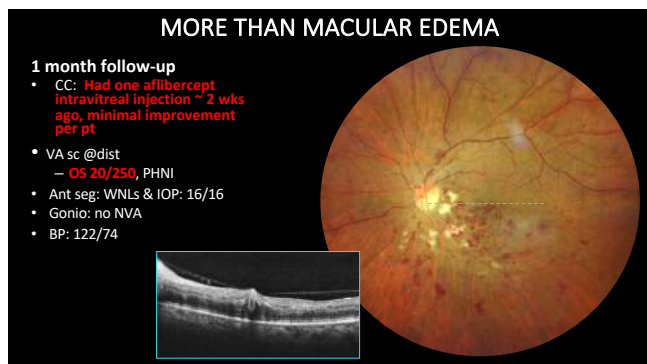
44



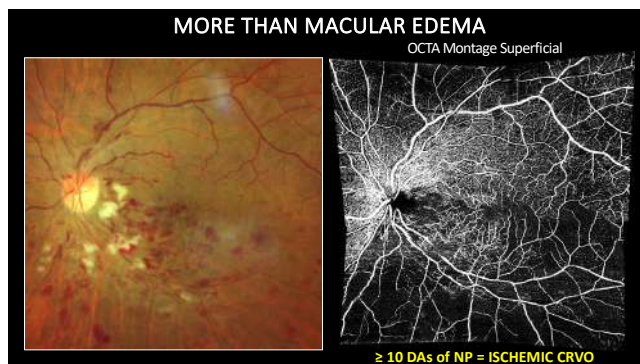
45



46

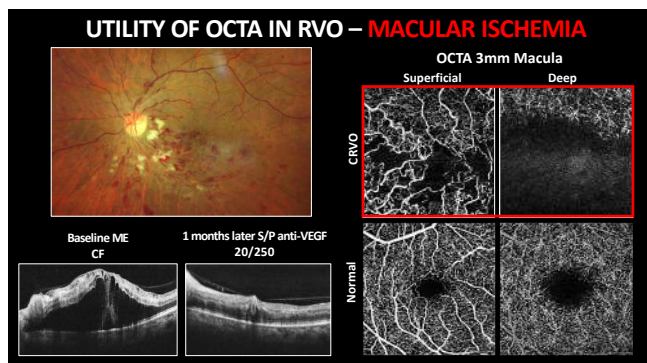


47

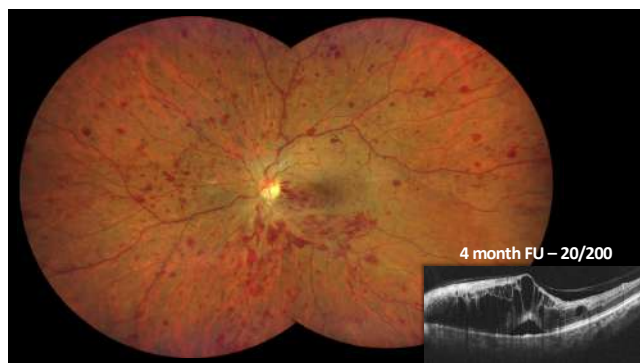


48

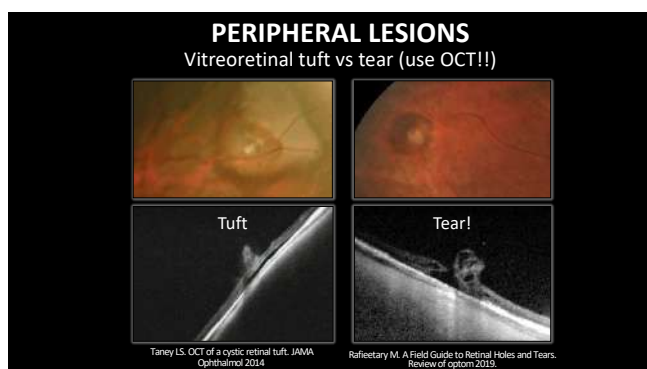




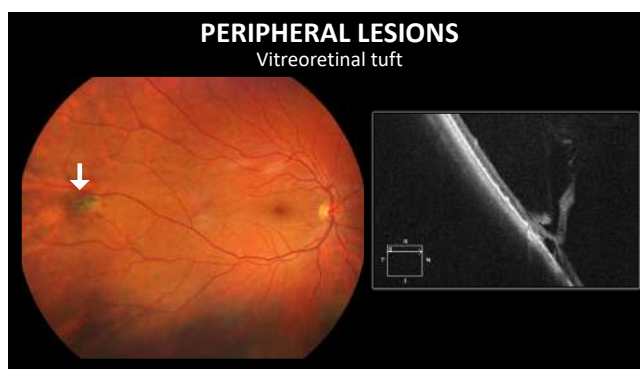
49



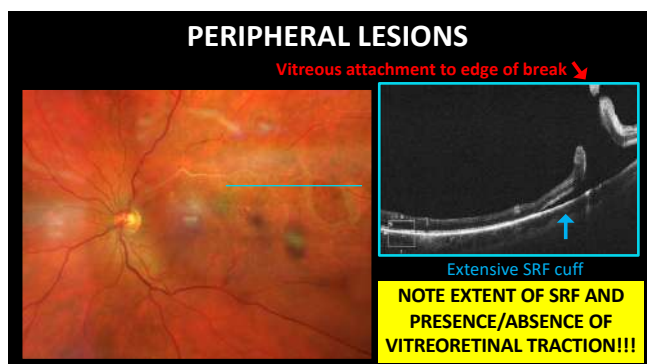
50



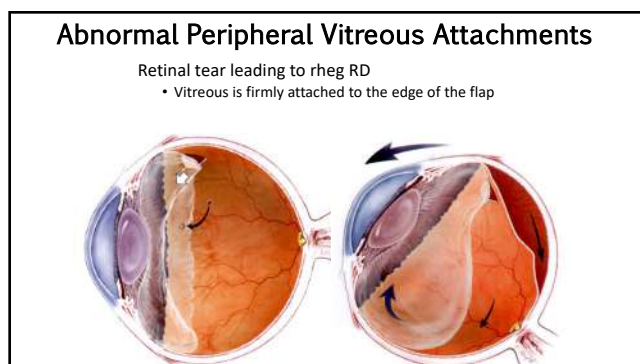
51



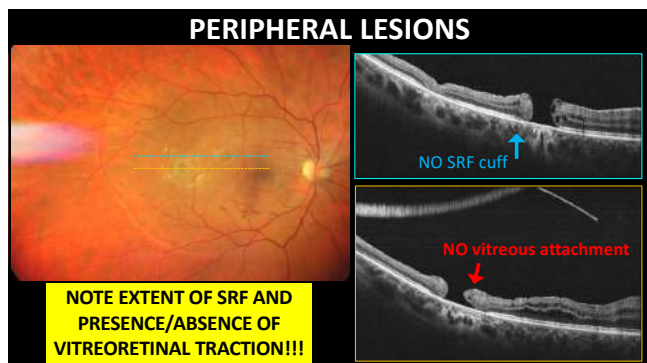
52



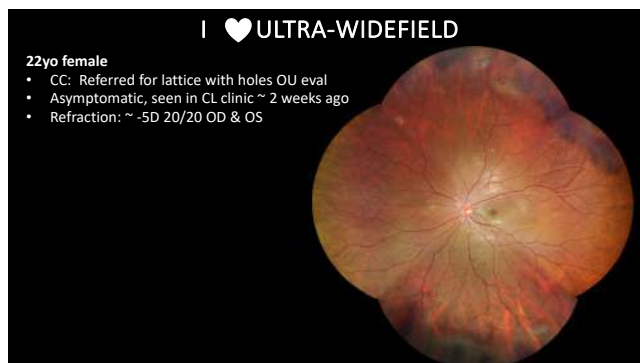
53



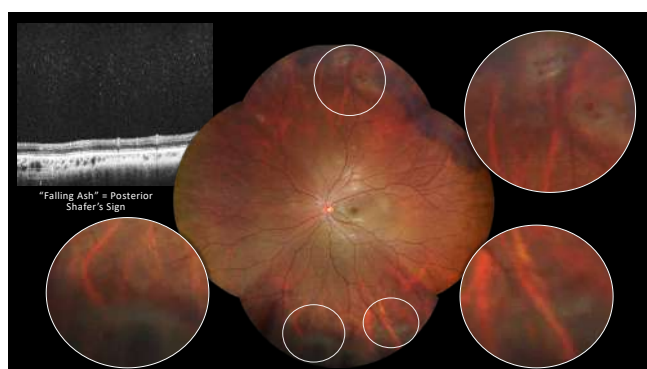
54



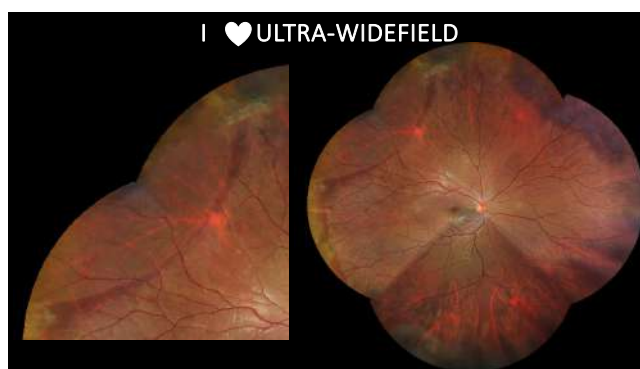55



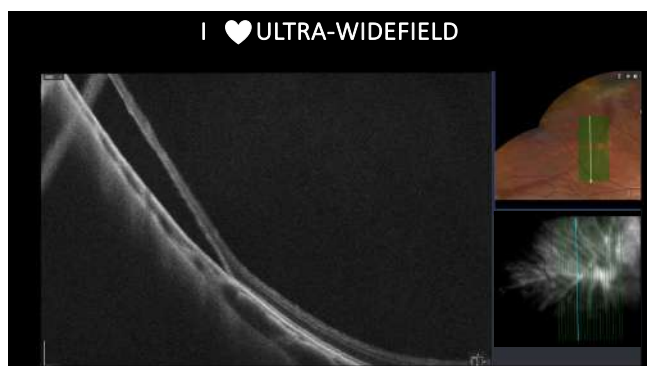
56



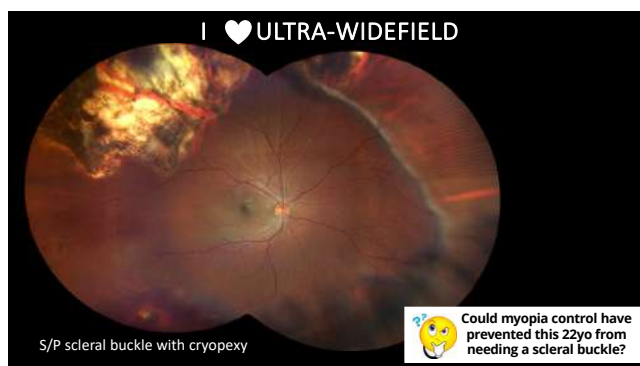
57



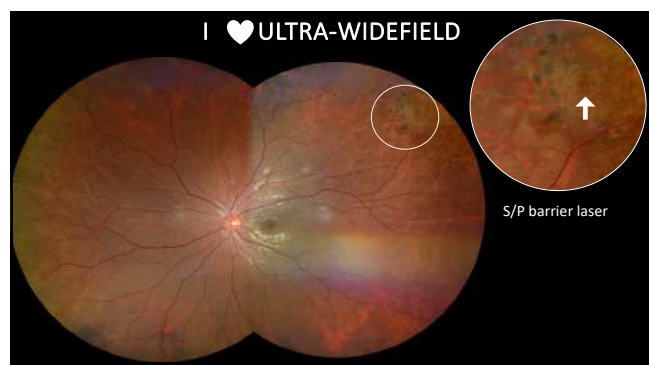
58



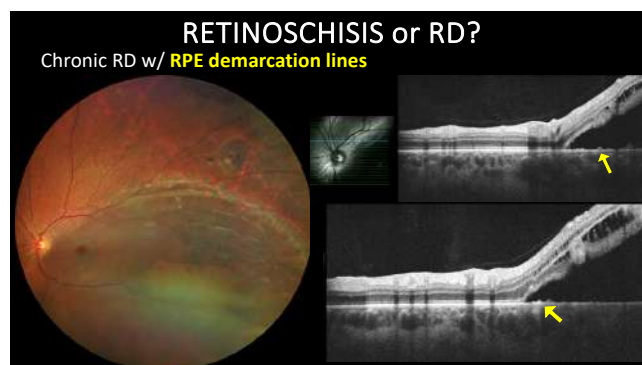
59



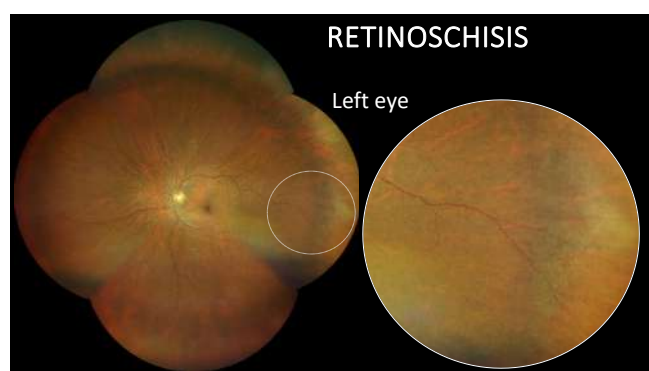
60



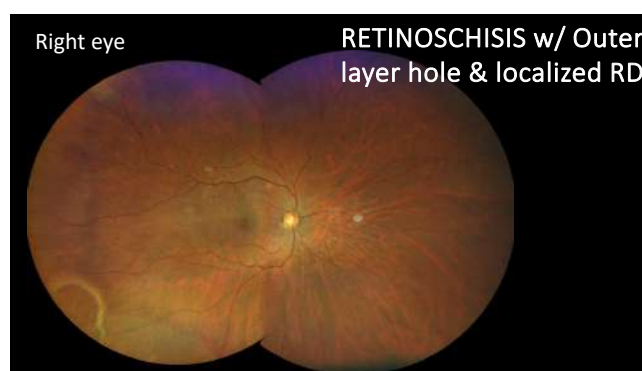
61



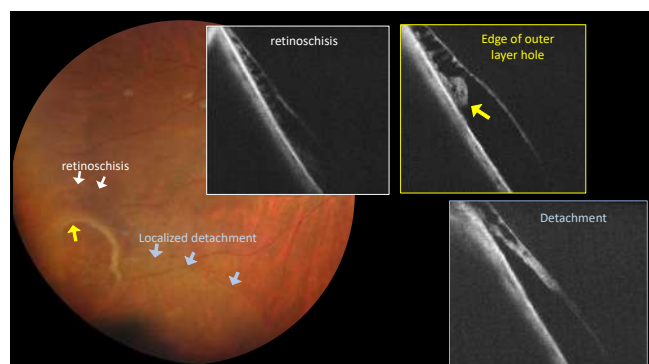
62



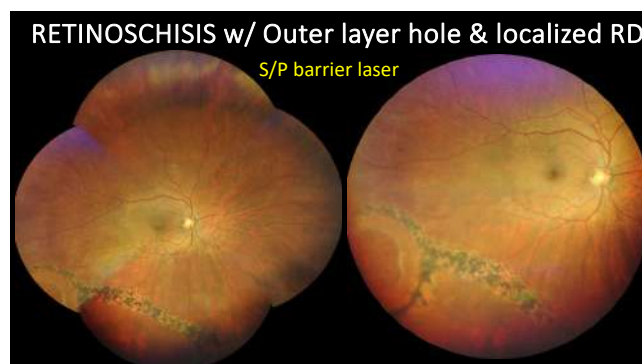
63



64

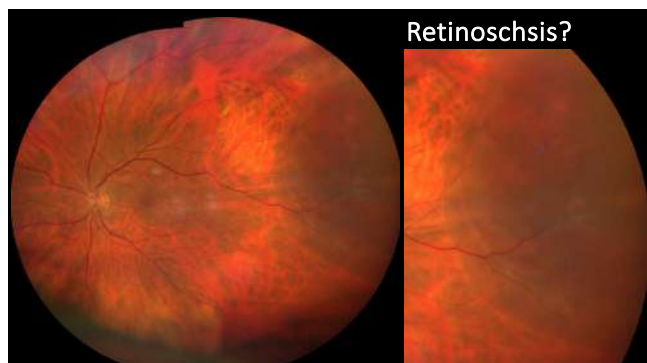


65

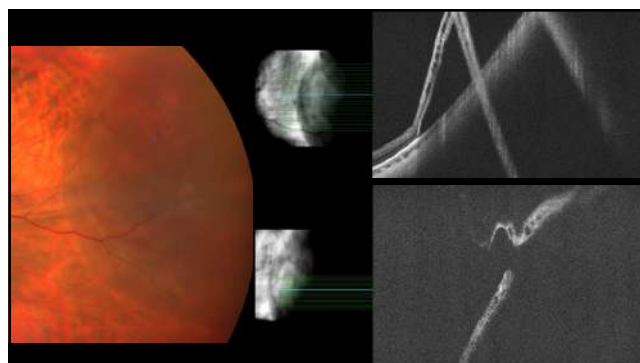


66

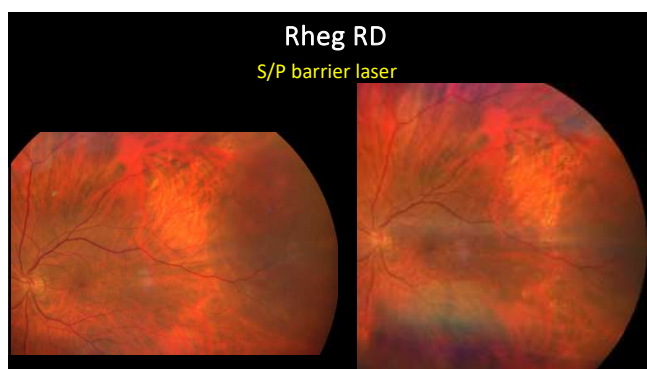



67



68



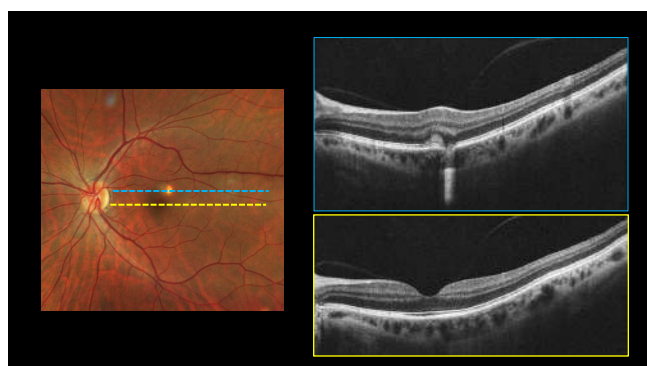
69

### ACUTE ONSET METAMORPHOPSIA

38yo Native American female

- CC: new onset floaters and slightly distorted vision OS x 3 days
- Oc Hx: LASIK OU 2010, pt reports there were "old scars" seen in the back of the eyes when she had LASIK done
- Med Hx: WNL
- BCVA :
  - OD: 20/20
  - OS: 20/25+2

70



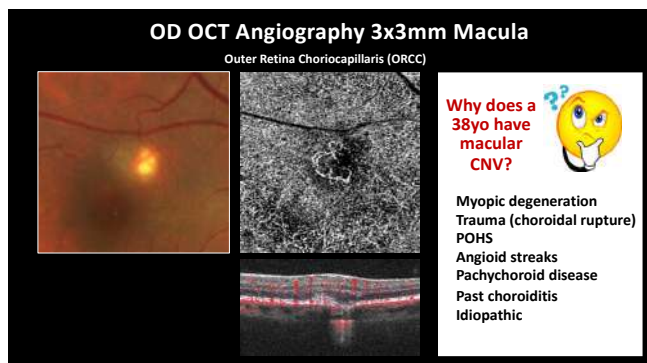
71

### OD OCT Angiography 3x3mm Macula

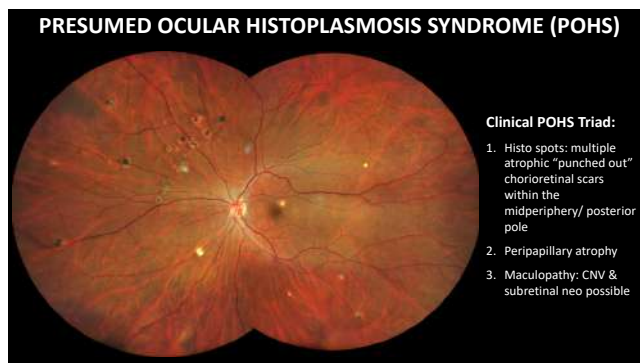
Outer Retina Choriocapillaris (ORCC)

Why does a 38yo have macular CNV? 🤔

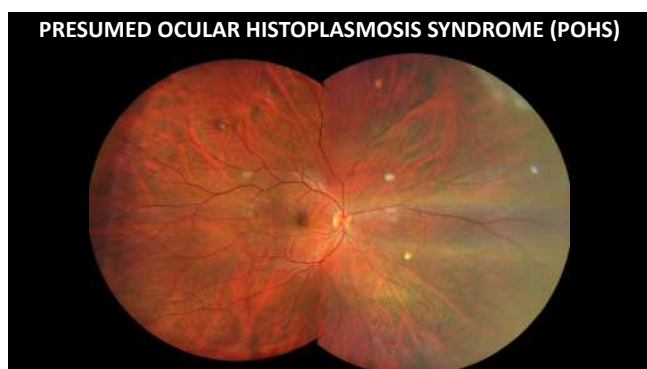
72



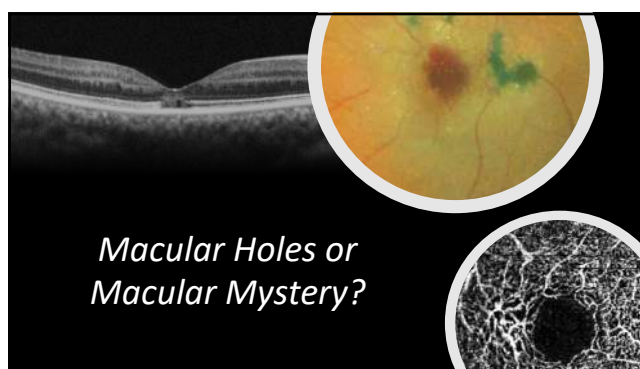73



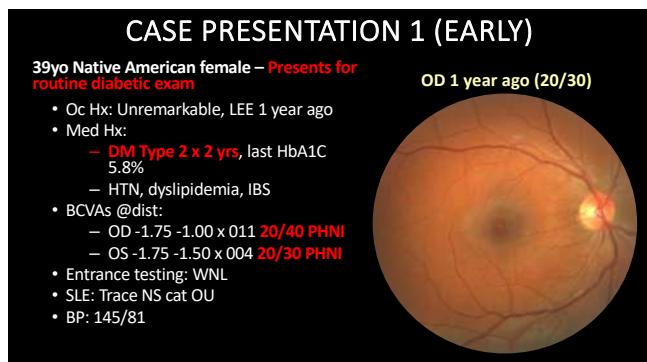
74



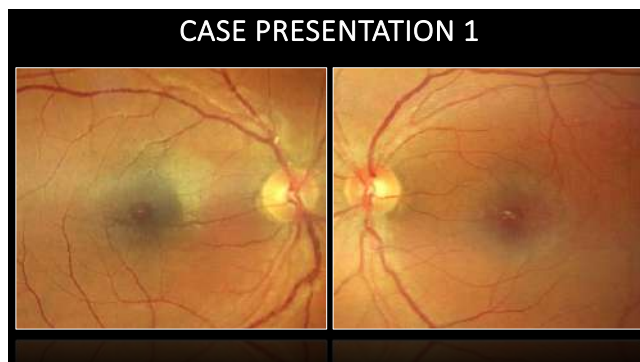
75



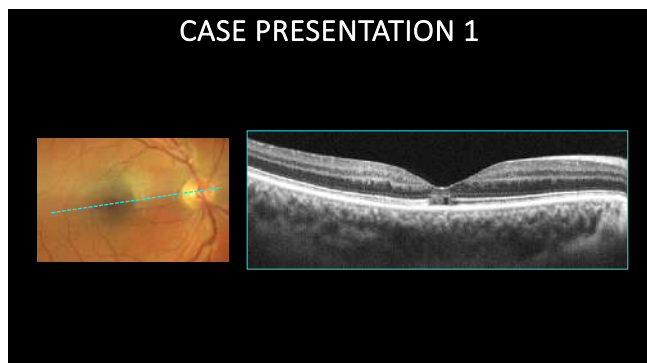76



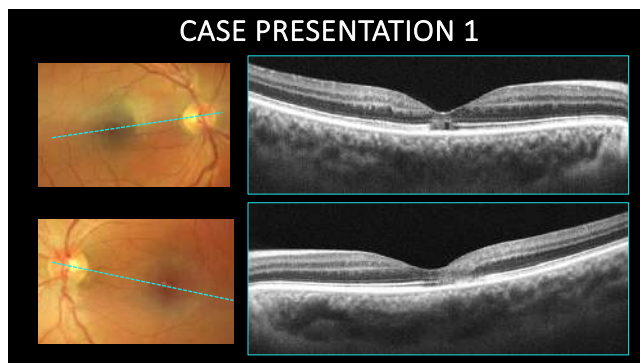
77



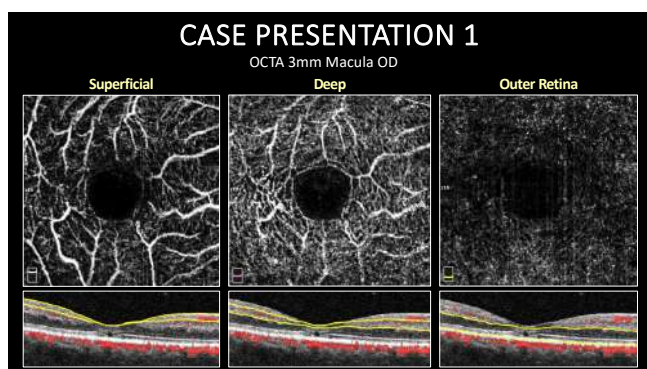
78



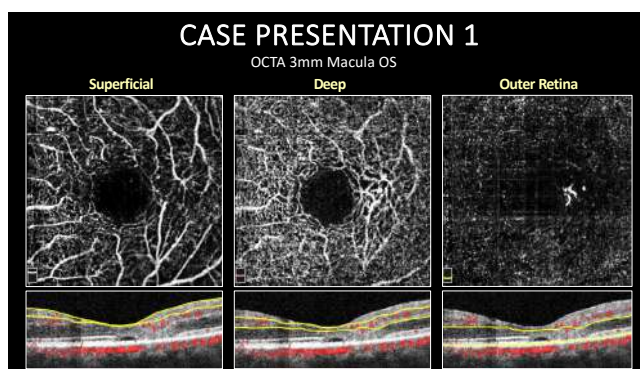
79



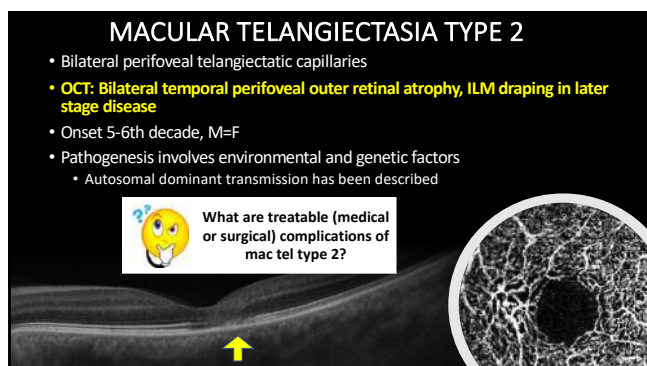
80



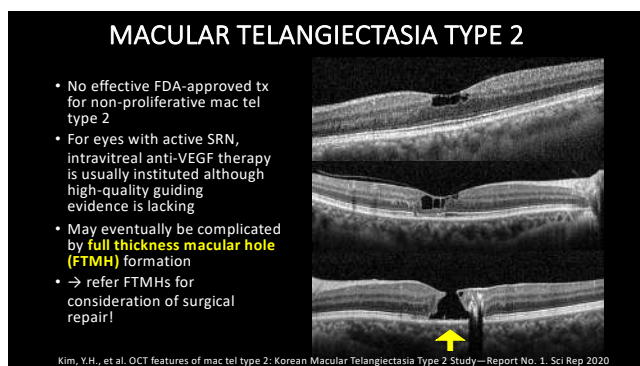
81



82



83




84



### Proliferative Mac Tel Type 2

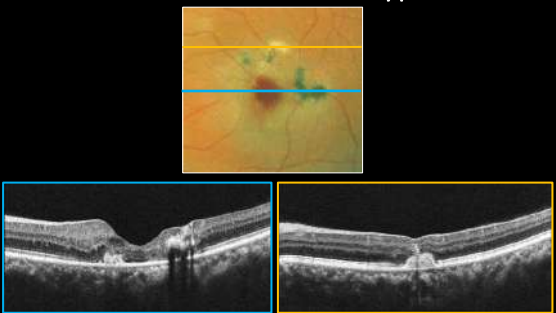
57yo Hispanic female – Referred from primary care for possible macular dystrophy/macular scarring OU

- CC: gradually progressive vision loss OU x several years
- Oc Hx: No known illness or fam Hx. No prior surg or trauma.
- Med Hx: Unremarkable
- BCVAs @dist:
  - OD 20/100 PHNI
  - OS 20/200 PHNI
- Entrance testing: WNL
- SLE: 1-2+ NS cat OU



85

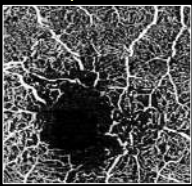
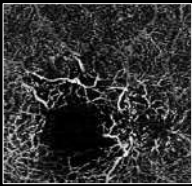
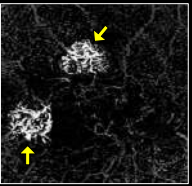



### Proliferative Mac Tel Type 2



86

### Proliferative Mac Tel Type 2

OCTA 3mm Macula OS

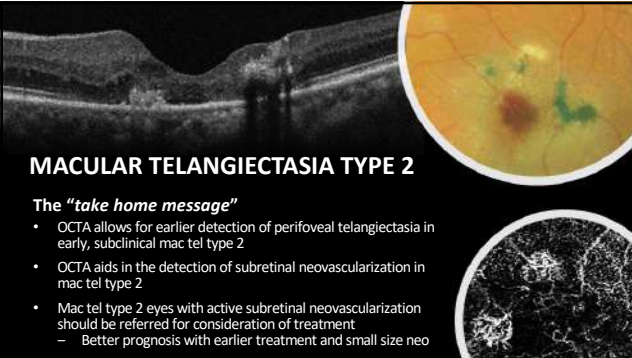
| Superficial   | Deep  | Outer Retina (Custom)   |
|---|---|---|
|   |   |   |
|  |  |  |

87

### MACULAR TELANGIECTASIA TYPE 2

The "take home message"

- OCTA allows for earlier detection of perifoveal telangiectasia in early, subclinical mac tel type 2
- OCTA aids in the detection of subretinal neovascularization in mac tel type 2
- Mac tel type 2 eyes with active subretinal neovascularization should be referred for consideration of treatment
  - Better prognosis with earlier treatment and small size neo




88

### MACULAR HEMORRHAGE

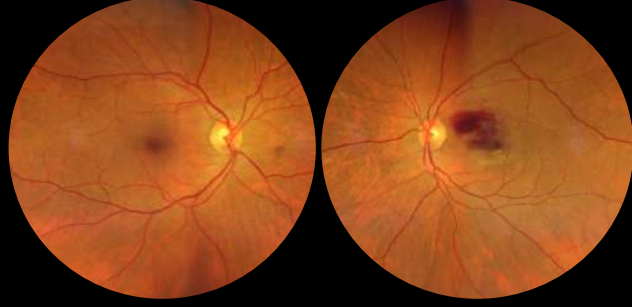
70yo female –blur and ↓vision OS for about 2-3 months

- Med Hx:
  - HTN (in office BP 131/83)
  - Type 2 DM x 12 yrs (last A1c 6.5%)
  - OSA on CPAP, ↑ chol, stage 3 CKD
- BCVAs @dist:
  - OD 20/20<sup>+</sup>, OS 20/150 PHNI
- Entrance testing: all WNLs other than central scotoma with facial amsler OS
- SLE: NS 1 cat OU
- IOPs: OD 12/ OS 14 mmHg

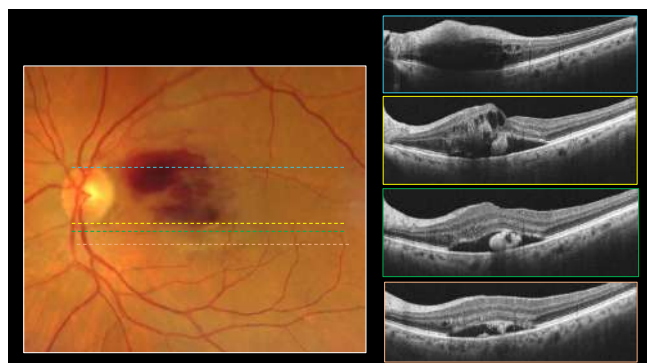


89

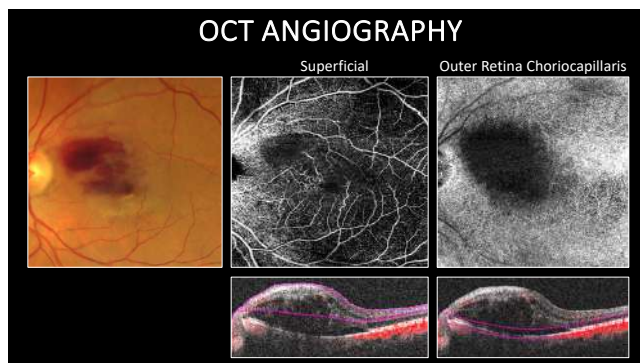
### MACULAR HEMORRHAGE



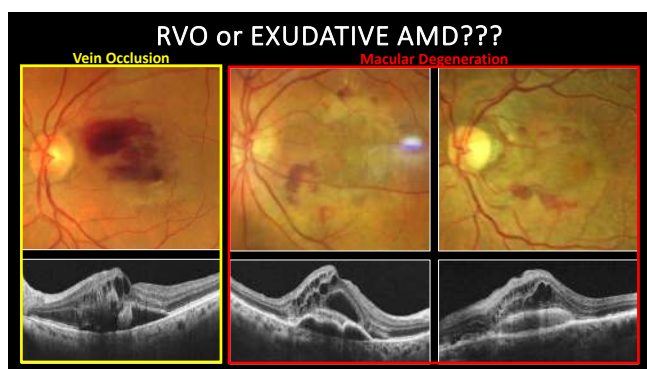
90



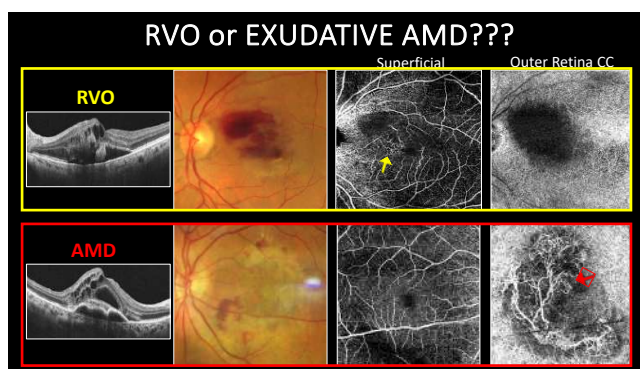
91



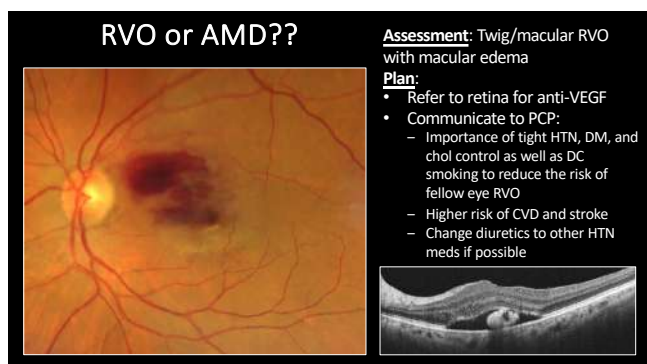
92



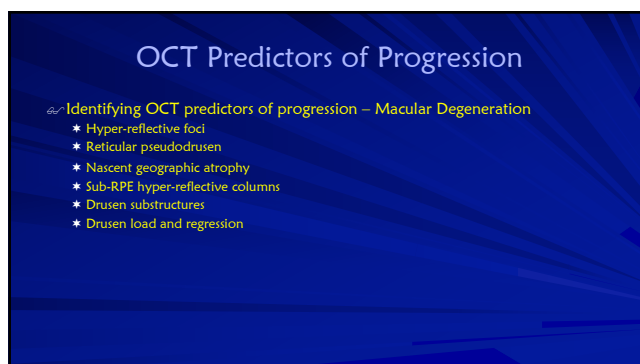
93



94

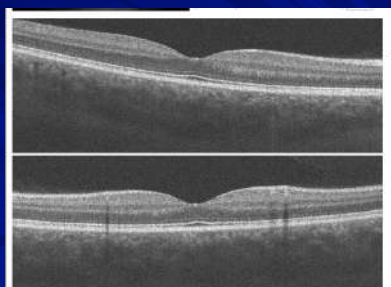


95



96

### Hypo versus Hyper Reflectance



97

### Can We Learn From These Pictures?



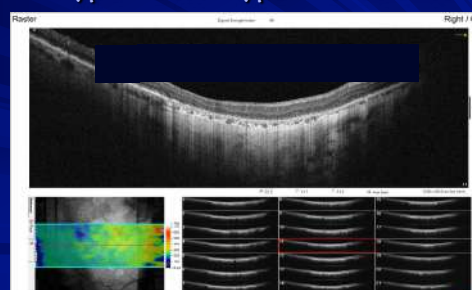
98

### Can We Learn From These Pictures?



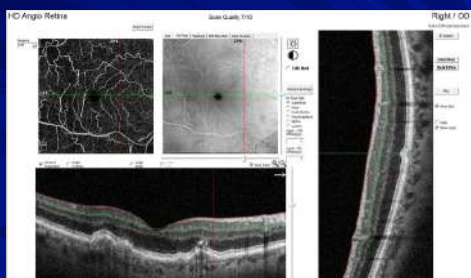
99

### Hypo versus Hyper Reflectance



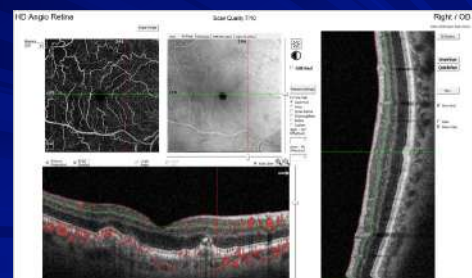
100

### OCT Predictors of Progression



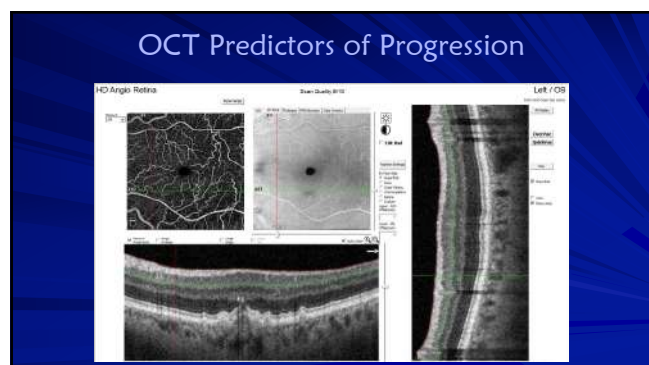
101

### OCT Predictors of Progression

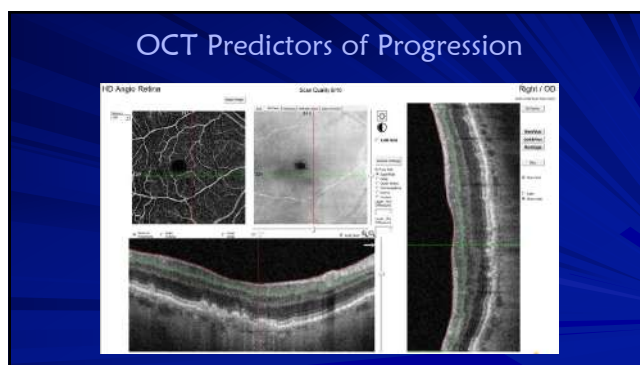


102

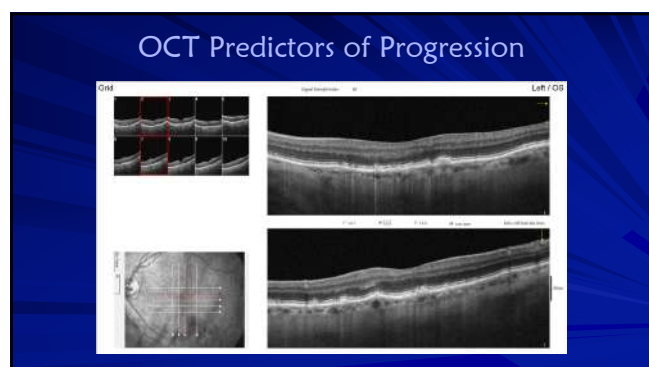




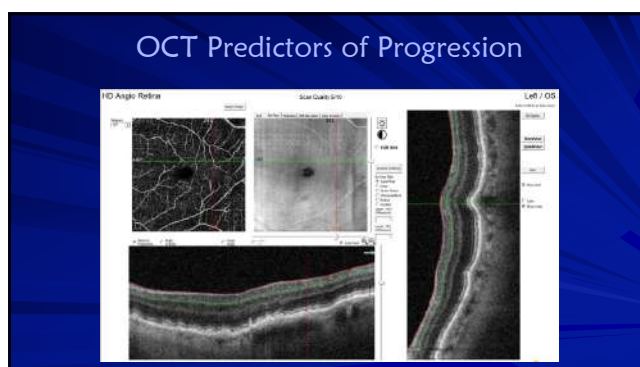
103



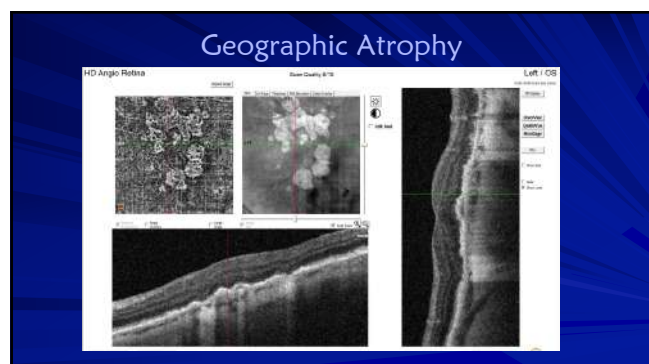
104



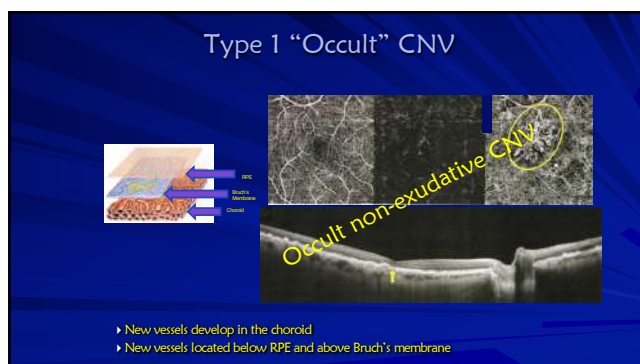
105



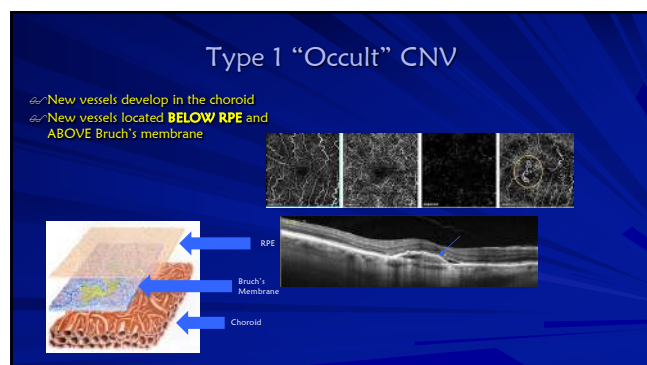
106



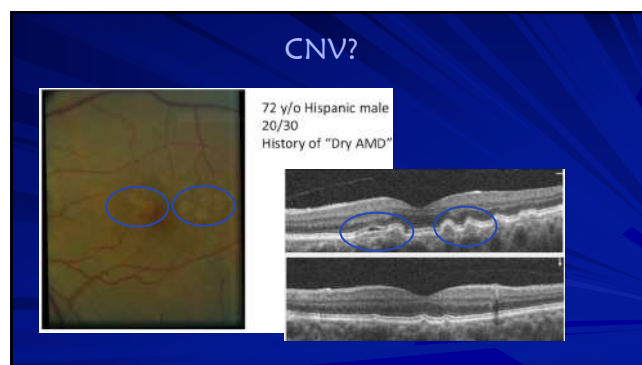
107



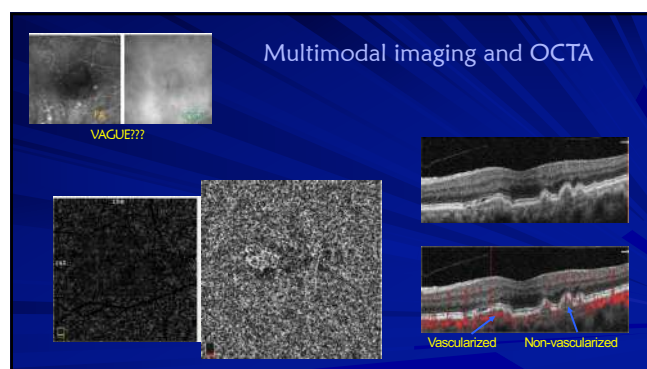
108



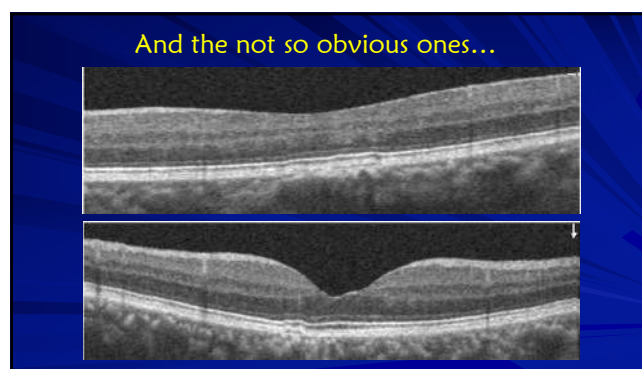
109



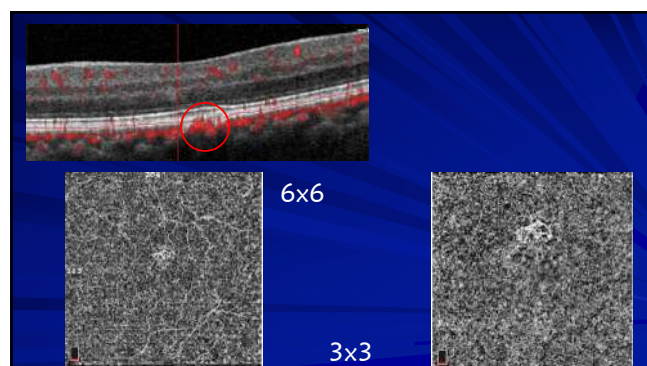
110



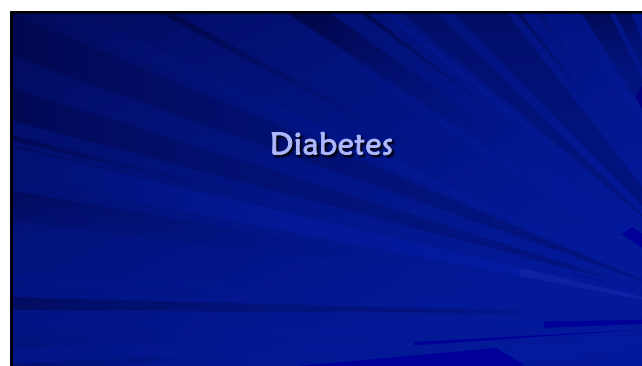
111



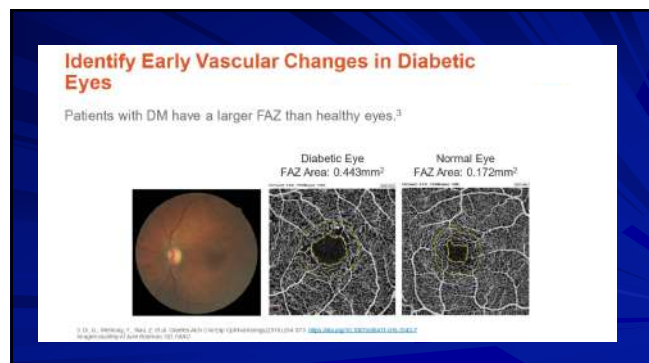
112



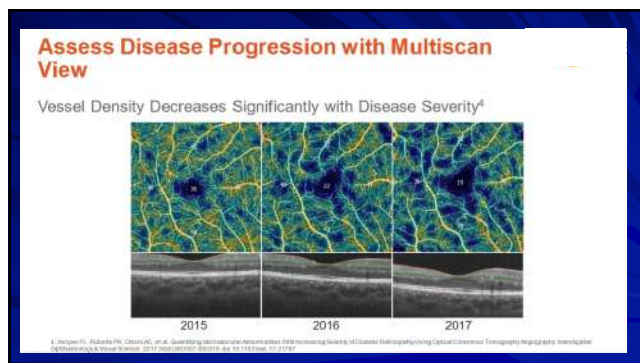
113



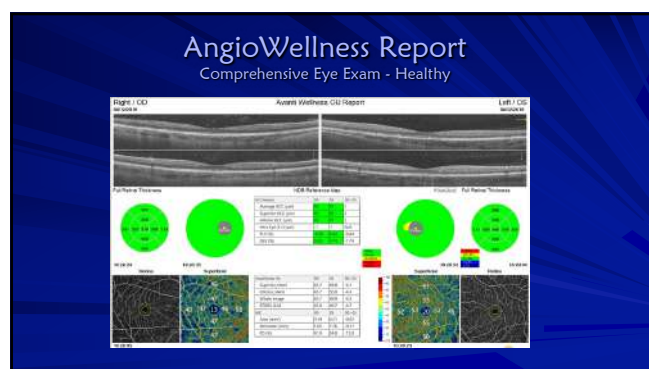
114



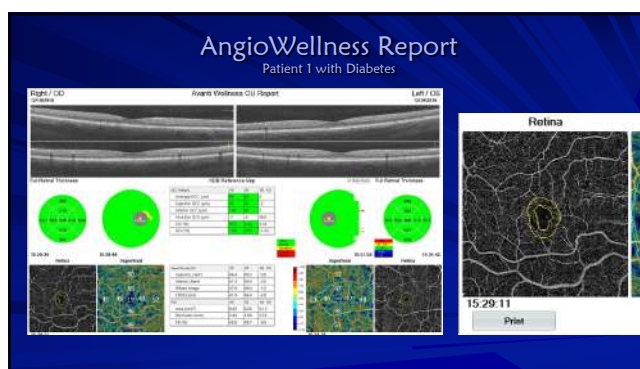
115




116



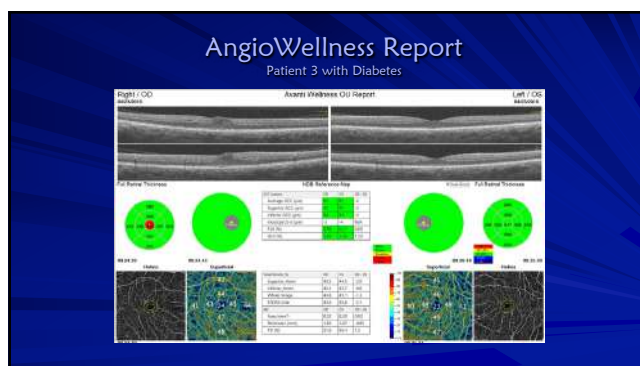
117



118

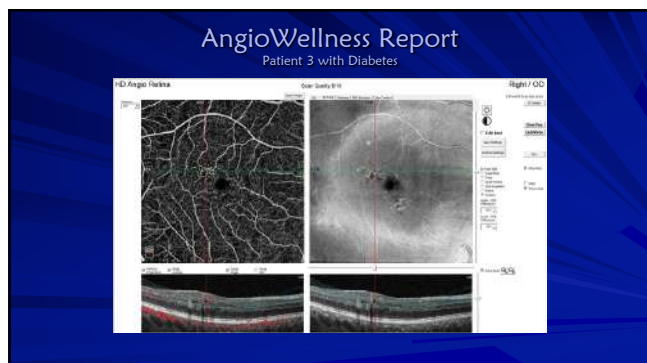


119



120



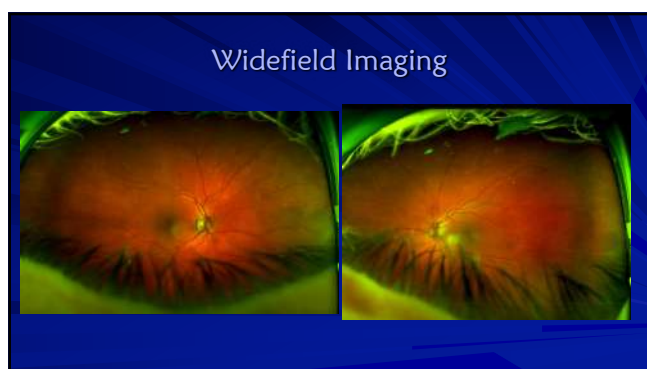

121

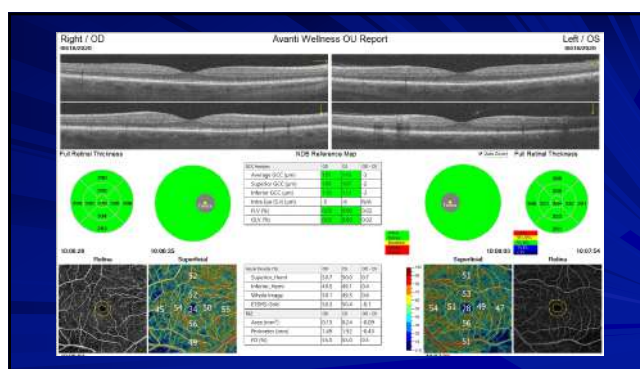
### 58-year-old man with diabetes

- New patient to the practice
- BS: unsure, last HbA1c unsure
- DM meds: metformin, glyburide, Invokana
- Vision 20/20
- Anterior segment: normal

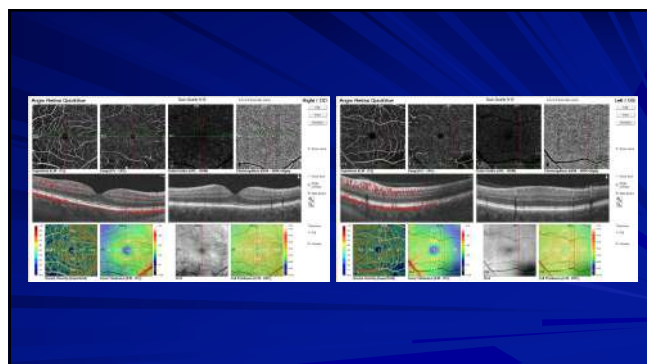
122



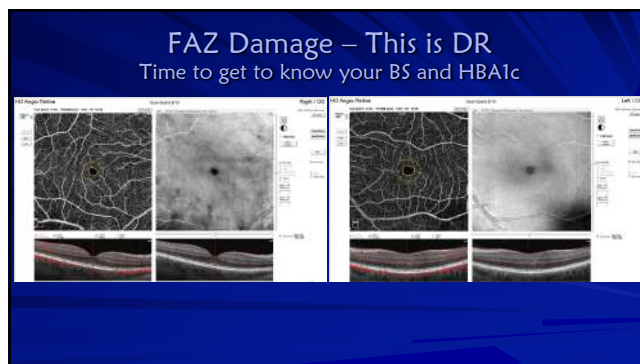
123



124



125



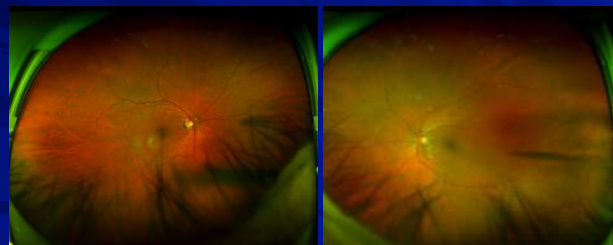
126

### 64-year-old man with diabetes

- BS: 134 this AM, last HbA1c 8.0
- DM meds: Novolog and Amaryl
- Vision 20/20
- Anterior segment: normal

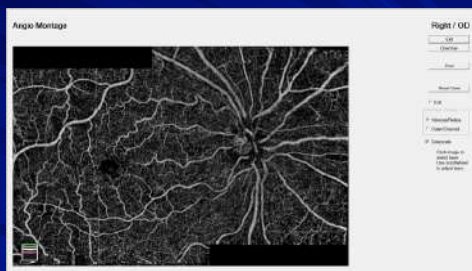
127

### Widefield Imaging



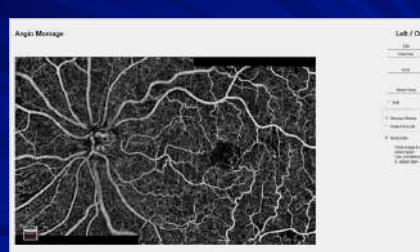
128

### 64-year-old man with diabetes



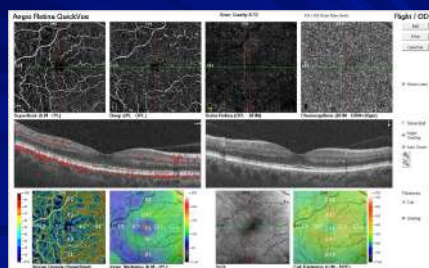
129

### 64-year-old man with diabetes



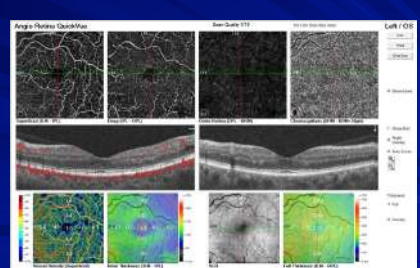
130

### 64-year-old man with diabetes

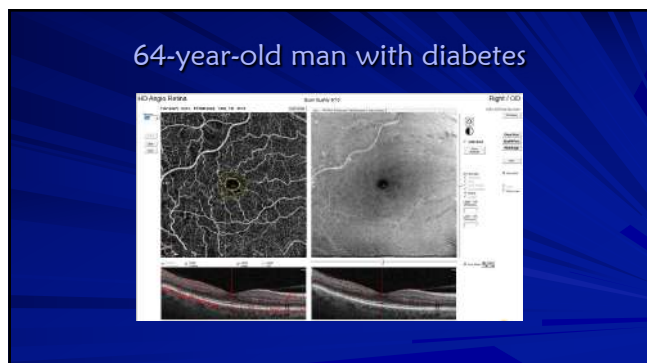

131

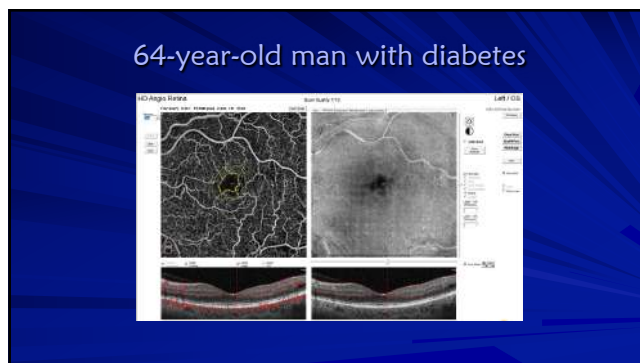### 64-year-old man with diabetes



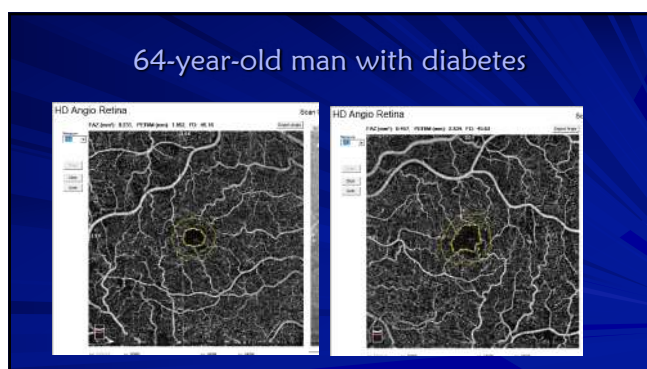132



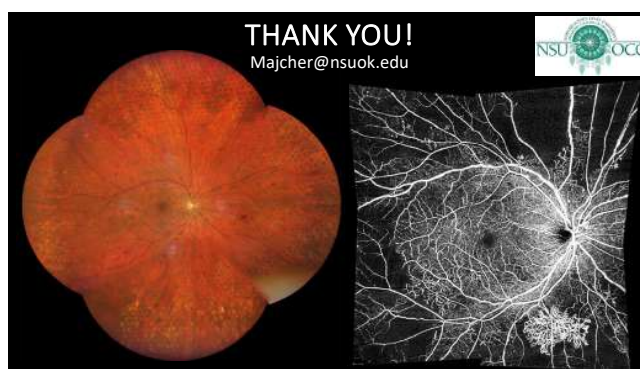
133



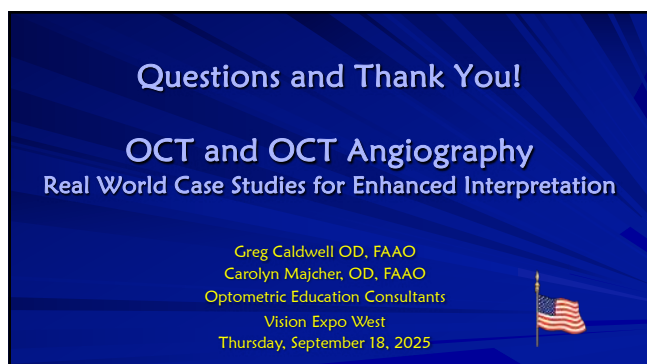
134



135



136



137